COMMUNITY ONCOLOGY

Electronically reprinted from March 2011

Original Research

Molecular tumor classification using a 92-gene assay in the differential diagnosis of squamous cell lung cancer

Robert S. McGee, MD, PhD,[1] Nicole C. Kesty, PhD,[2] Mark G. Erlander, PhD,[2] and Catherine A. Schnabel, PhD[2]

[1] Randolph Hospital, Asheboro, NC, and [2] bioTheranostics, Inc., San Diego, CA

Recent progress in targeted cancer therapies for advanced non-small cell lung cancer (NSCLC) has expanded the selection of optimal treatment beyond platinum-based chemotherapy and identified differential response and safety profiles based on histology. Given that accurate pathologic classification is of increasing clinical interest, molecular diagnostics presents a standardized approach to determining the tissue of origin and the histologic subtype in conjunction with routine evaluation. The objective of this retrospective case study was to characterize the clinical utility of molecular profiling in diagnoses and treatment of squamous cell lung cancer by (1) comparing molecular results with pathologic correlates in lung classification and subclassification, (2) characterizing case features to better understand the clinical indications for molecular testing, and (3) evaluating the potential clinical impact based on how test results were utilized in rendering clinical diagnoses and treatment selections. Sixty-two cases predicted to be squamous cell lung cancer by a 92-gene molecular profiling assay (CancerTYPE ID) were evaluated. Specimen characteristics and abstracted pathology information revealed that the clinical indications for CancerTYPE ID were high-grade tumors with equivocal histopathology and/or immunohistochemistry and were utilized to potentially resolve a differential diagnosis (47%), to identify an unknown/uncertain primary tumor origin (32%), or to confirm a primary tissue origin (21%). A physician survey of clinical strategy pre and post assay showed that CancerTYPE ID guided, confirmed, or changed the primary tumor site for treatment purposes in 85% of the 20 evaluable cases and the tumor subtype in 60% of the tumors tested. Results of this case series present preliminary evidence that molecular profiling provides additional information on tumor site and subtype in conjunction with standard clinical evaluation.

Lung cancer is the leading cause of cancer-related mortality in both men and women and is associated with an estimated 160,000 deaths annually in the United States.[1,2] Approximately 85% of lung cancers are non-small cell type carcinomas (NSCLCs), which include adenocarcinoma (30%–40%), squamous cell carcinoma (25%–30%), and large cell carcinoma (10%–15%) histologies. Traditionally, classification of NSCLC into glandular and squamous subtypes had no therapeutic impact; however, recent clinical trials for NSCLC demonstrate that response to therapy may vary by histology.[3–6]

In a study comparing combination therapy of either pemetrexed (Alimta) or gemcitabine (Gemzar) with cisplatin in advanced-stage NSCLC, patients with nonsquamous cell carcinomas had significantly better survival with the pemetrexed combination, whereas the gemcitabine combination was more effective against squamous cell carcinomas.[4,7] Nonsquamous cell histology has also been associated with better outcomes in patients treated with the anti-VEGF (vascular endothelial growth factor) antibody bevacizumab (Avastin) in combination with carboplatin/paclitaxel.[3,8] Moreover, an increased risk of hemorrhagic or fatal bleeding events has been associated with bevacizumab and sorafenib (Nexavar), a multikinase inhibitor, in patients with squamous cell histology.[3,9] Therefore, precise histologic subclassification and detection of squamous cell components in lung neoplasms have distinct treatment implications.

Histologic subclassification techniques

Lung carcinoma is routinely subclassified into its histologic variants based on morphology. How-

Manuscript received December 30, 2010; accepted February 16, 2011.

Correspondence to: Catherine A. Schnabel, PhD, bioTheranostics, Inc., 9640 Towne Centre Drive, Suite 200, San Diego, CA 92121; telephone: 858-587-5884; fax: 858-587-5871; e-mail: cathy.schnabel@biotheranostics.com.

Commun Oncol 2010;8:123–131 © 2011 Elsevier Inc. All rights reserved.

ever, varied histopathology and cellular heterogeneity are well-recognized features of these tumors, and reportedly less than 35% of lung carcinomas are of a single cell type.[10–12] Immunohistochemistry (IHC) has improved the precision of lung cancer classification with the use of particular markers, such as thyroid transcription factor-1 (TTF-1), p63, and cytokeratin (CK) 5/6.[13–16] In addition, the effectiveness of IHC is limited by technical inconsistencies in staining procedures, suboptimal sensitivities/specificities of individual markers, and nonstandardized interpretation.[17–19] Definitive diagnoses are further confounded in cases where diagnostic material is limited and in poorly differentiated tumors in particular.[19–21]

Although morphologic classification continues to be widely used, aided by IHC staining and other techniques, incorporation of molecular features can provide increased resolution and a standardized approach that complements current classification paradigms. CancerTYPE ID (bioTheranostics, Inc., San Diego, CA) is a reverse transcription-polymerase chain reaction (RT-PCR)-based molecular diagnostic test to determine the primary tissue of origin for 39 tumor types. It has a sensitivity of 87% and a specificity of > 99%.[22] Differential expression of 87 informative genes and 5 reference genes is the basis of this test. It is routinely performed on formalin-fixed, paraffin-embedded tissues, which requires approximately 300–500 tumor cells, and is a molecular extension to traditional IHC analysis.

The retrospective study reported here examined the clinical utility of the CancerTYPE ID test in facilitating a diagnosis of squamous cell lung cancer in tumor samples submitted for testing in 2009. The objectives were to conduct a preliminary evaluation of the clinical relevance of CancerTYPE ID test results in rendering diagnoses and to estimate its added clinical value in patient management.

Methods

CancerTYPE ID assay

The 92-gene real-time RT-PCR assay (CancerTYPE ID) was developed as previously described.[22] Samples used in the CancerTYPE ID assay were formalin-fixed, paraffin-embedded tissue sections generated from tumor biopsies. Each tissue section was stained with hematoxylin and eosin for microscopic evaluation, and the areas with high tumor-cell density were marked by a pathologist. The tumor-enriched areas were isolated by manually scraping tissue off the slide or by employing laser microdissection to remove interfering tissue elements (normal cells, necrotic areas, fibrocytes, and lymphocyte infiltrations) to provide samples with a higher percentage of tumor cells. In this study, 53% of the specimens were harvested using laser microdissection.

The enriched tumor cells were lysed, with total RNA extracted and reverse transcribed to generate cDNA for the CancerTYPE ID assay, as previously described.[22] The RT-PCR assay was performed on an ABI 7900HT instrument using Taq Man technology (Applied Biosystems, Foster City, CA). The gene-expression profile for each patient sample was compared with the CancerTYPE ID tumor gene-expression database using a proprietary algorithm to predict the most likely primary tissue of tumor origin and histologic subtype.

Results are reported as ranked probabilities with single top predictions of primary tissue of origin and histologic subtype. The algorithm reports other possible cancer types in rank order based on probability, reflecting overlap in similar gene-expression profiles, and also calculates primary tissue types and histologic subtypes that can be "ruled out" with > 95% confidence. In these cases, 35% of the CancerTYPE ID results were single predictions of squamous cell lung cancer. Consistent with the heterogeneity inherent in these tumors, 53% reported two possible predictions, and 11% contained ≥ three predictions. Second-rank results mainly included other squamous (such as skin) and lung (adenocarcinoma and neuroendocrine) predictions.

Study design

This study was based on a retrospective review of all 64 cases reported as squamous cell lung cancer by CancerTYPE ID in 2009. The objectives were to characterize the indications for use of the CancerTYPE ID test in the differential diagnosis of squamous cell lung tumors and to survey the impact of molecular results in current practice and clinical decision-making. A total of 62 cases had complete pathology reports available (evaluable cohort, Table 1); two case reports were excluded: one due to incomplete information that could not be expanded and one due to a report that was not in English. Independent review board approval was granted with an exemption certification for the study.

Histopathologic evaluation

All tumor samples were formalin-fixed, paraffin-embedded tissue sections. Descriptions of the tumor specimens, including biopsy site, suspected primary site(s), morphologic characteristics, tumor grading, and IHC analyses, were obtained from the sample requisition form and the pathology report submitted with each sample. During the collection of histologic grading data, tumor samples that were described as moderately to poorly differentiated were classified as poorly differentiated. If more than one description was listed (eg, squamous cell or transitional), the diagnosis was captured as not otherwise specified (NOS). When abstracting the interpretation of the prima-

ry site, if only one tissue was listed as the most likely primary tumor site, it was captured as the suspected primary for confirmation. When multiple potential primaries were listed, it was considered a "differential diagnosis." Cases where the primary site was described as "unknown" or "other" (with specific tissues listed) were categorized as "unknown/uncertain." When no primary tumor origin was listed, the specimen was classified as "unspecified."

Clinician survey

For the clinician survey, molecular results were ranked by the strength of the CancerTYPE ID prediction. Using this approach, approximately one-third of the cases contained test results that predicted squamous cell lung cancer as single predictions; these were considered high confidence calls. The purpose of this component of the study was to conduct a preliminary inspection of potential clinical utility of CancerTYPE ID in a small series of cases wherein results were analytically compelling. Treating medical oncologists from these 22 cases were contacted to determine the diagnosis and treatment information using a standardized questionnaire. Specific questions in the questionnaire follow: (1) In regard to the primary tumor tissue type, would you say that the CancerTYPE ID guided/confirmed, changed, or did not affect your treatment decisions? (2) In regard to histology, would you say that the CancerTYPE ID guided/confirmed, changed, or did not affect your treatment decisions? (3) Which clinical diagnosis did you use to treat your patient? (4) What cancer treatment regimen did you use for this patient?

Results

Patient demographics, specimen characteristics, and histologic characterizations for the 62 evaluable cases resulting in squamous cell lung tumor predictions by molecular testing are given in Table 1. The mean age of the patients was 64 years. The lymph nodes (27%) and lungs (21%) represented approximately half of the biopsy sites. Clinical specimens included surgical, core-needle, and fine-needle aspirate biopsies. A majority of the cases in which grading was reported consisted of poorly differentiated epithelial tumors.

Antibody-based classification was performed predominantly through CK7, CK20, and TTF-1 IHC analysis in 68%, 69%, and 68% of the cases, respectively (Figure 1); p63 and CK5/6, markers suggesting squamous cell differentiation, were utilized in 21% and 15% of the cases, respectively. The number of IHC markers assayed ranged from 0 to 35, with a mean of 8.9 markers/sample and a median of 7.0 markers/sample.

An integrated schematic of the corresponding pathology data provided for the 62 evaluable squamous cell lung samples is shown in Figure 2. A lung origin was suspected or included in the differential diagnoses in less than 50% of cases (n = 29); squamous cell morphology was noted in 47% of cases (n = 29) and contained supportive IHC data in 21% of cases (n = 13). Abstracted information from the pathology reports indicated that samples were submitted for molecular testing to resolve a differential diagnosis that included the lungs as a suspected site of tumor origin (47%), to confirm a suspected primary site that did not include the lungs (21%), or to identify an unknown/uncertain primary tumor origin or one that was not specified (32%).

Summary data for cases included in the clinician survey are shown in Table 2. Clinical sources for the table were extracted from pathology reports submitted with each case and from physician responses to the survey in regard to the particular cases. In 77% of these cases, CancerTYPE ID results were consistent with clinicopathologic correlates (squamous

TABLE 1

Demographics and specimen characteristics of 62 evaluable squamous cell lung tumor samples

Characteristic	Value[a]
Gender, male/female	60%/40%
Age, yr	64 ± 13[b]
Biopsy type, n (%)	
Surgical	32 (52%)
Core needle	26 (42%)
Fine-needle aspirates/cell blocks	4 (7%)
Biopsy site, n (%)	
Lymph node	17 (27%)
Lungs	13 (21%)
Liver	9 (15%)
Head and neck	8 (13%)
Brain	3 (5%)
Other	12 (19%)
Histologic staging, n (%)	
Carcinoma	
Well	0 (0%)
Moderate	6 (10%)
Poor	19 (31%)
Undifferentiated	4 (7%)
NOS	19 (31%)
Adenocarcinoma	
Well	0 (0%)
Moderate	1 (2%)
Poor	6 (10%)
Undifferentiated	0 (0%)
NOS	5 (8%)
Neoplasm	
Undifferentiated	1 (2%)
NOS	1 (2%)
Histologic diagnosis, n (%)	
Squamous cell carcinoma	29 (47%)
Adenocarcinoma	13 (21%)
Carcinoma, NOS	9 (15%)
Other non-small cell carcinoma	7 (11%)
Carcinoma with neuroendocrine features	2 (3%)
Neoplasm	2 (3%)

NOS = not otherwise specified

[a] Percentages may not sum to 100% due to rounding.

[b] Data are expressed as mean ± standard deviation.

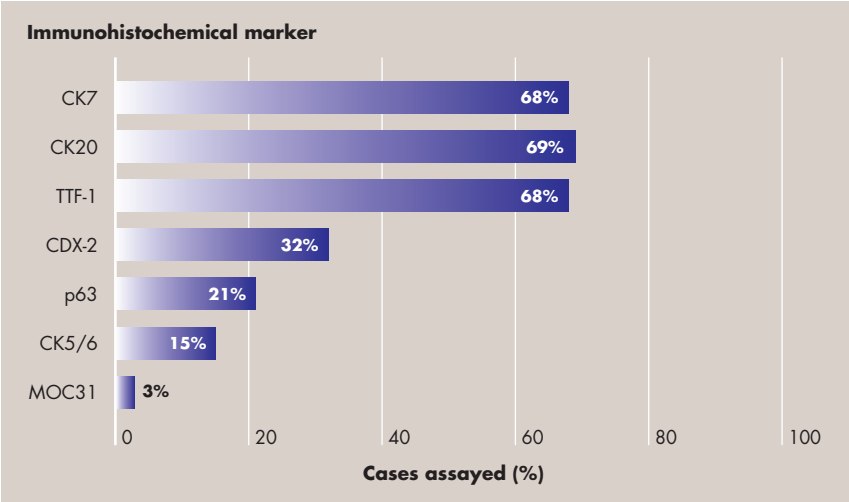

FIGURE 1 Distribution of immunohistochemical markers used to diagnose the evaluable squamous cell lung tumor samples prior to molecular profiling in the CancerTYPE ID assay.

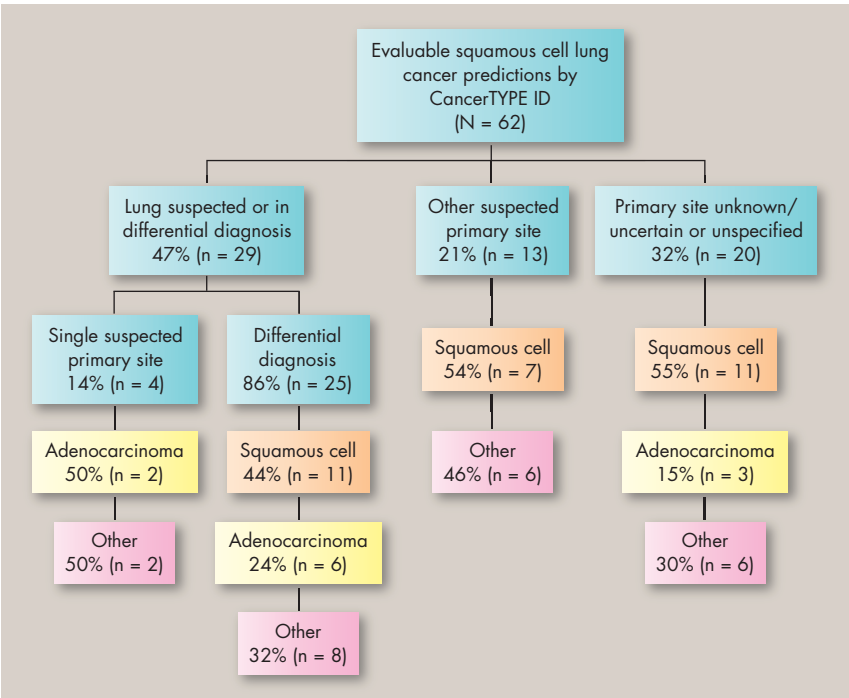

FIGURE 2 Suspected primary tumor site and histologic diagnosis prior to molecular profiling in the CancerTYPE ID assay.

cell morphology or lung origin in diagnosis). Notably, molecular classification provided additional information about the site of tumor origin in several diagnostic categories. In six cases, the pathologic diagnosis was reported as an unknown primary cancer, and molecular testing predicted a potential anatomic site of tumor origin. Molecular testing confirmed clinical suspicion in nine cases where the lungs were proposed as a primary tumor site. Moreover, among these nine cases, six of them contained multiple differentials ranging from two to six possible sites of tumor origin, and molecular testing provided tumor sites that could be "ruled out" in addition to predicting the lungs as a possible primary tumor site. Regarding histologic subtype, three of the cases were diagnosed as NSCLC, and molecular testing further subclassified the tumor as squamous cell cancer. In more than 50% of these cases, squamous cell morphology was noted; however, primary sites of tumor origin were not definitively diagnosed.

Treatment selection information is also summarized in Table 2. Therapeutic regimens for which molecular results were incorporated based on physician responses were predominantly broad-based chemotherapy doublets consistent with a diagnosis of squamous cell lung cancer. In two cases, the folate antimetabolite pemetrexed, which is contraindicated for squamous cell lung cancer, was applied.

Physician responses to a standardized questionnaire were used to assess whether the additional data provided by CancerTYPE ID (site of tumor origin and subtype) had any impact on clinical decision-making (Table 2, physician-reported responses). Prior to molecular profiling, the suspected primary tumor site included the lungs as a possibility in 41% of patients, was unknown/uncertain in 27% of patients, was not suspected to be the lungs in 23% of patients, and was not specified in 9% of patients. Based on clinicians' responses, the clinical diagnosis after molecular testing was reported as the lungs for 15 tumors (68%), the head and neck for 2 tumors, the colorectum for 1 tumor, and unknown for 1 tumor. No data were available for the remainder of the cases (two physicians failed to respond to the post-ID questionnaire and one did not provide a final diagnosis). Two patients were surgically treated and two patients progressed too rapidly for any therapy and were referred to hospice.

Therefore, CancerTYPE ID results guided or confirmed the primary tumor site for treatment purposes in 50% of cases (10 of 20) and changed the clinical diagnosis of the

TABLE 2

Disposition of cases identified with high confidence as squamous cell lung tumors by the CancerTYPE ID assay

Information from pathology reports							Physician-reported responses			
No.	Gender	Age, yr	Biopsy site	Histology	Immunohistochemistry	Suspected primary site(s) prior to molecular testing	Clinical diagnosis after molecular testing	Diagnostic utility: primary site	Diagnostic utility: subtype	Treatment
1	M	59	Lung	Carcinoma, non-small cell	CK7+, CK20–, CDX2–,TTF-1–, PSA–, CK34BE12+, CK5/6+, CD56–	Lung, colorectal	Lung, squamous	Changed	Guided/ confirmed	Carboplatin/ *nab*-paclitaxel
2	M	82	Lung	Poorly differentiated carcinoma, squamous transitional cell	CK7+, CK20–, TTF-1–, p63+, CK903+, thrombomodulin+	Pancreas	Pancreas, lung[a]	Changed	Changed	Gemcitabine/ carboplatin
3	M	75	Bone	Carcinoma, metastatic squamous cell	CK7–, CK20–, CDX2–, TTF-1–, PSA–, synaptophysin–, p63+, CK5/6+, CA19.9–, CEA–	Unknown	Lung, squamous	Changed	Guided/ confirmed	Carboplatin/ paclitaxel
4	M	73	Axillary lymph node	Carcinoma, non-small cell squamous or transitional cell	CK7+, CK20–, TTF-1–, PSA–, thrombomodulin+, BCA225–, CEA–	Unknown	Unknown	Changed	Did not affect	Surgery
5	M	77	Tonsil	Undifferentiated neoplasm; favor squamous	CK7–, CK20–, CDX2–, S100–, HMB45–, PLAP–, CD138–, synaptophysin–, cKit–, CD34+, CD68+, CAM 5.2–, HMWK–, pancytokeratin–, inhibin–, chromogranin–, p63–, CK5/6–, calretinin–, TdT–, cCD3–, CD45–, vimentin+, MART-1–, CD20–, ALK1–, CD30–, CD43–, CD1a–, CD21–, CD31–, lysozyme–, myeloperoxidase–	Unknown	Lung, squamous	Changed	Did not affect	Docetaxel/ carboplatin
6	F	45	Cervical lymph node	Carcinoma, non-small cell	CK7+, CK20–, TTF-1–, ER–, CK–	Head and neck, lung	Lung, non-small cell	Changed	Guided/ confirmed	Carboplatin/ docetaxel
7	F	75	Lung	Moderately differentiated carcinoma, squamous cell	TTF-1–, CK5/6+, CK8+	Anus, unknown	Lung, squamous	Changed	Changed	Docetaxel/ carboplatin/ radiation therapy
8	F	68	Liver	Carcinoma, metastatic squamous cell	p63+	Unknown	Lung, non-small cell	Guided/ confirmed	Guided/ confirmed	Paclitaxel/ carboplatin
9	M	75	Para-tracheal lymph node	Poorly differentiated carcinoma, non-small cell	CK7+, CK20+, CDX2–, TTF-1+, surfactant–	Lung	Lung	Guided/ confirmed	Did not affect	Pemetrexed/ paclitaxel/ carboplatin

Table 2 continued on the following page

TABLE 2 *continued*

Disposition of cases identified with high confidence as squamous cell lung tumors by the CancerTYPE ID assay

Information from pathology reports							Physician-reported responses			
No.	Gender	Age, yr	Biopsy site	Histology	Immunohistochemistry	Suspected primary site(s) prior to molecular testing	Clinical diagnosis after molecular testing	Diagnostic utility: primary site	Diagnostic utility: subtype	Treatment
10	M	79	Axillary lymph node	Carcinoma, metastatic squamous cell	S100–, HMB45–, AE1/AE3+, HMWK+, CD3–, CD20–	Unknown	Lung, squamous	Guided/ confirmed	Guided/ confirmed	Carboplatin/ paclitaxel
11	F	48	Soft tissue, buttock	Carcinoma, metastatic squamous, clear-cell type	CK7+, CK20+, TTF-1–, CD10–, AE1/AE3+, Ber-EP4+, CK5/6+	Lung, breast, urothelium, ovary, endometrium, pancreas	Lung	Guided/ confirmed	Guided/ confirmed	Progressed too quickly
12	M	71	Bone	Carcinoma, metastatic, neuroendocrine features	CK7+, CK20–, TTF-1–, PSA– synaptophysin+, AE1/AE3+, chromogranin–, PASP–	Pancreas, upper GI, lung, prostate	Lung	Guided/ confirmed	Did not affect	Carboplatin/ paclitaxel
13	F	59	Clivus	Undifferentiated carcinoma	S100–, synaptophysin+, cKit+, pancytokeratin+, NSE+, p53+, EMA+, LCA–, chromogranin–, EBV–	Sinonasal cavity	Head and neck, squamous cell	Guided/ confirmed	Guided/ confirmed	Etoposide/ carboplatin
14	M	51	Lung	Poorly differentiated adenocarcinoma	CK7+, CK20–, TTF-1–, PSA–, CK5/6–	Lung, colon	Lung, squamous cell	Guided/ confirmed	Changed	Surgery
15	M	46	Lung	Poorly differentiated adenocarcinoma	CK7+, CK20–, TTF-1–	Lung	Lung, non-small cell	Guided/ confirmed	Changed	Docetaxel/ GH302/ capecitabine/ sorafenib
16	F	59	Neck	Carcinoma, metastatic squamous cell	No data provided in pathology report	Not specified	Lung	Guided/ confirmed	Did not affect	1. Cisplatin/ pemetrexed 2. Irinotecan/ capecitabine
17	M	69	Liver	Poorly differentiated carcinoma, metastatic squamous cell	CK7–, CK20–, CDX2–, TTF-1–, PSA–, CD10–, HMWK+, p63+, LMWK–	Kidney, anorectum, lung, head and neck	Lung, squamous cell	Guided/ confirmed	Guided/ confirmed	Platinum/ docetaxel
18	M	48	Aryepiglottic fold	Moderately differentiated carcinoma, squamous cell	No data provided in pathology report	Head and neck	Head and neck	Did not affect	Did not affect	Not provided
19	M	38	Liver	Adenocarcinoma	CK7 equivocal, CK20–, CDX2–, TTF-1–, PSA–, AE1/AE3+, LCA–, HAS–, S100–	Colorectum	Colorectum	Did not affect	Did not affect	FOLFOX
20	M	78	Liver	Moderately differentiated carcinoma, squamous cell	No data provided in pathology report	Esophagus	Esophagus	Did not affect	Did not affect	Hospice
21	M	58	Peritoneum	Poorly differentiated carcinoma, squamous cell	S100–, HMB45–, synaptophysin–, CK5/6+, p63+, CD56–	Lung, esophagus, urinary bladder, skin	No data available	No data available	No data available	No data available

Table 2 continued on the following page.

TABLE 2 *continued*

Disposition of cases identified with high confidence as squamous cell lung tumors by the CancerTYPE ID assay

Information from pathology reports							Physician-reported responses			
No.	Gender	Age, yr	Biopsy site	Histology	Immunohistochemistry	Suspected primary site(s) prior to molecular testing	Clinical diagnosis after molecular testing	Diagnostic utility: primary site	Diagnostic utility: subtype	Treatment
22	F	66	Cervical lymph node	Poorly differentiated carcinoma, metastatic squamous cell	CK7+, CK20–, TTF-1–, pancytokeratin+, CEA+, mucicarmine–	Not specified	No data available	No data available	No data available	No data available

M = male; F = female; CEA = carcinoembryonic antigen; CK = cytokeratin; MART = melan A; PSA = prostate-specific antigen; TTF = thyroid transcription factor; GI = gastrointestinal; FOLFOX = folinic acid, fluorouracil, and oxaliplatin

[a] Pancreas and lung considered in treatment regimen decision

primary tumor site in an additional 35% of cases (7 of 20). In regard to the histologic subtype, CancerTYPE ID guided, confirmed, or changed the subtype in 60% of the tumors tested (12 of 20).

Discussion

A preliminary evaluation of the clinical utility of the CancerTYPE ID test was examined through this retrospective study of cases predicted to be squamous cell lung carcinoma in a diagnostic setting. The specimen characteristics associated with these cases submitted for molecular testing in 2009 suggested the clinical indication for CancerTYPE ID included high-grade metastatic tumors where specimen availability may be limited (~ 50% core-needle and fine-needle aspiration biopsies; Table 1). Additionally, CancerTYPE ID was used to confirm or reduce possibilities in differential diagnoses (68%) or to classify cases of unknown origin (24%). In the evaluable cohort, 47% of cases included the lungs in the differential diagnosis, and for 32% of cases, the primary tumor site was unknown/uncertain or unspecified (Figure 2). Furthermore, squamous cell morphology was noted in 47% of the cases and contained supportive IHC data in 21%.

Therefore, CancerTYPE ID had the potential to provide diagnostic utility in both the determination of the tissue of origin and the classification of histologic subtype. CancerTYPE ID may represent an additional analytic approach to histopathologic evaluation to aid in strengthening diagnosis.

There is a growing need for standardized methods for classifying lung carcinomas, as treatment and side effects specific to different subtypes are becoming more widely recognized. It is estimated that approximately 20%–30% of NSCLC samples do not show sufficient morphologic differentiation to be amenable to classification by light microscopy and thus require further investigation by IHC or other diagnostic techniques.[23] However, despite advances in protocols, the effectiveness of IHC may be limited due to technical inconsistencies in immunostaining techniques and the lack of standardization in interpretation.[17–19,24] In addition, interpretation of the analysis is further challenged by samples that are poorly differentiated and/or lack cytologic and architectural features.[19–21] Currently, there is no molecular-based test used in routine practice to facilitate histopathologic diagnoses. Therefore, the need for adjunctive, standardized assays to aid in tumor typing and subclassification is evident, particularly in cases where standard morphologic evaluation and IHC do not lead to a definitive diagnosis.

CancerTYPE ID uses gene-expression profiling to determine the tissue of origin; to distinguish among the different subtypes of lung cancers with no prior morphologic or IHC identification required; and to reduce the diagnostic uncertainty associated with differential diagnoses, metastatic cancers, cancers of an unknown primary, and others not confirmable through other diagnostic or histopathologic means alone. It has demonstrated a sensitivity of 80%–90% in the identification of squamous cell lung carcinomas in small blinded test sets and internal validation studies.[22,25] Although these test sets provide an initial estimate of assay accuracy, further studies aimed at evaluating the performance characteristics of CancerTYPE ID with a diverse and large number of tumor samples are ongoing, and are required to establish its clinical validity.

In addition to CancerTYPE ID, which is an mRNA-based RT-PCR assay using the differential expression of 92 genes, another commercially available diagnostic assay based on microRNA expression subclassifies diagnosed NSCLC tumors.[26,27] These molecular tests have been optimized for formalin-fixed, paraffin-embedded clinical samples, have demonstrated a high degree of sensitivity and specificity, and can be readily integrated into current diagnostic workflows.

A key objective of this small study

was to investigate whether the availability of molecular profiling data in the context of standard clinical evaluation was associated with a change in the clinical diagnoses rendered and/or in treatment selection. Physician-reported feedback using a standardized questionnaire demonstrated that results from molecular testing guided, confirmed, or changed the primary tumor site for treatment purposes in 85% of the 20 evaluable cases and guided, confirmed, or changed the tumor subtype in 60% of the tumors tested. These preliminary results support the clinical utility of CancerTYPE ID as an additional diagnostic tool, which may have an impact on clinical decision-making in conjunction with standard clinicopathologic evaluation.

Until recently, treatment decisions for patients with lung cancer have been largely empirical. With this empirical approach, the outcomes of patients with NSCLC have only marginally improved during the past several decades. Of the estimated 222,520 patients expected to be diagnosed with lung cancer in 2010, 71% of these patients will die in the same year from this malignancy.[28]

Prognoses and treatment of metastatic cancer rely fundamentally on the identification of the site of tumor origin. This is particularly relevant in the case of squamous cell cancer, where each anatomic site has its own particular spread pattern and prognosis. For instance, in the United States, the 5-year patient survival rate is approximately 15% for NSCLC, whereas for all sites and stages in the head and neck region, the 5-year survival rate averages 59%.[29,30] Emerging clinical data have resulted in paradigmatic shifts in the treatment of squamous cell cancer, with an increasing number of novel strategies available, including both chemotherapy and targeted therapy-based approaches. These data further underscore the significance of both the identification of the tumor site as the first step to understanding cellular context and tumor subclassification to guide optimal therapy. Molecular tools such as CancerTYPE ID have demonstrated potential in providing additional data to aid in diagnosis and in supporting decision-making in the era of increasingly sophisticated oncology treatment protocols.

Limitations of this study include the retrospective design, a small sample set, and the lack of direct clinical validation with confirmed diagnoses or long-term clinical follow-up. However, the design allowed examination in a more heterogeneous patient population than is representative of actual daily clinical practice.

Conclusion

This study underscores the potential clinical utility of the CancerTYPE ID assay in the differential diagnosis of lung tumors. Incorporation of CancerTYPE ID into current diagnostic procedures may facilitate more accurate diagnoses leading to consequent patient benefit, such as the potential to use clinically appropriate site-directed therapy. Prospective clinical trials for further validation of the clinical utility of this test are ongoing.

Acknowledgments: The authors thank Loretta L. Nielsen, PhD, for writing support and Amy Marrs for administrative support.

References

1. American Cancer Society. Cancer facts and figures 2008. Atlanta: American Cancer Society; 2008:1–72.

2. Jemal A, Siegel R, Ward E, et al. Cancer statistics, 2008. CA Cancer J Clin 2008;58:71–96.

3. Johnson DH, Fehrenbacher L, Novotny WF, et al. Randomized phase II trial comparing bevacizumab plus carboplatin and paclitaxel with carboplatin and paclitaxel alone in previously untreated locally advanced or metastatic non-small-cell lung cancer. J Clin Oncol 2004;22:2184–2191.

4. Scagliotti GV, Parikh P, von Pawel J, et al. Phase III study comparing cisplatin plus gemcitabine with cisplatin plus pemetrexed in chemotherapy-naive patients with advanced-stage non-small-cell lung cancer. J Clin Oncol 2008;26:3543–3551.

5. Zinner RG, Novello S, Peng G, Herbst R, Obasaju C, Scagliotti G. Comparison of patient outcomes according to histology among pemetrexed-treated patients with stage IIIB/IV non-small-cell lung cancer in two phase II trials. Clin Lung Cancer 2010;11:126–131.

6. Tan EH, Rolski J, Grodzki T, et al. Global Lung Oncology Branch trial 3 (GLOB3): final results of a randomised multinational phase III study alternating oral and i.v. vinorelbine plus cisplatin versus docetaxel plus cisplatin as first-line treatment of advanced non-small-cell lung cancer. Ann Oncol 2009;20:1249–1256.

7. Scagliotti G, Hanna N, Fossella F, et al. The differential efficacy of pemetrexed according to NSCLC histology: a review of two phase III studies. Oncologist 2009;14:253–263.

8. Sandler A, Yi J, Dahlberg S, et al. Treatment outcomes by tumor histology in Eastern Cooperative Group Study E4599 of bevacizumab with paclitaxel/carboplatin for advanced non-small cell lung cancer. J Thorac Oncol 2010;5:1416–1423.

9. Scagliotti G, Novello S, von Pawel J, et al. Phase III study of carboplatin and paclitaxel alone or with sorafenib in advanced non-small-cell lung cancer. J Clin Oncol 2010;28:1835–1842.

10. Roggli VL, Vollmer RT, Greenberg SD, McGavran MH, Spjut HJ, Yesner R. Lung cancer heterogeneity: a blinded and randomized study of 100 consecutive cases. Hum Pathol 1985;16:569–579.

11. Dunnill MS, Gatter KC. Cellular heterogeneity in lung cancer. Histopathology 1986;10:461–475.

12. Brambilla E, Travis WD, Colby TV, Corrin B, Shimosato Y. The new World Health Organization classification of lung tumours. Eur Respir J 2001;18:1059–1068.

13. Kargi A, Gurel D, Tuna B. The diagnostic value of TTF-1, CK 5/6, and p63 immunostaining in classification of lung carcinomas. Appl Immunohistochem Mol Morphol 2007;15:415–420.

14. Ring BZ, Seitz RS, Beck RA, et al. A novel five-antibody immunohistochemical test for subclassification of lung carcinoma. Mod Pathol 2009;22:1032–1043.

15. Wu M, Wang B, Gil J, et al. p63 and TTF-1 immunostaining: a useful marker panel for distinguishing small cell carcinoma of lung from poorly differentiated squamous cell carcinoma of lung. Am J Clin Pathol 2003;119:696–702.

16. Wu M, Szporn AH, Zhang D, et al. Cytology applications of p63 and TTF-1 immunostaining in differential diagnosis of lung cancers. Diagn Cytopathol 2005;33:223–227.

17. Tan D, Zander DS. Immunohistochemistry for assessment of pulmonary and pleural neoplasms: a review and update. Int J Clin Exp Pathol 2008;1:19–31.

18. Pelosi G, Sonzogni A, Viale G. The classification of lung carcinoma: time to change the morphology-based approach? Int J Surg

Pathol 2010;18:161–172.

19. Cataluña JJ, Perpiñá M, Greses JV, Calvo V, Padilla JD, Paris F. Cell type accuracy of bronchial biopsy specimens in primary lung cancer. Chest 1996;109:1199–1203.

20. Thomas JS, Lamb D, Ashcroft T, et al. How reliable is the diagnosis of lung cancer using small biopsy specimens? Report of a UKCCCR Lung Cancer Working Party. Thorax 1993;48:1135–1139.

21. Edwards SL, Roberts C, McKean ME, Cockburn JS, Jeffrey RR, Kerr KM. Preoperative histological classification of primary lung cancer: accuracy of diagnosis and use of the non-small cell category. J Clin Pathol 2000;53:537–540.

22. Ma XJ, Patel R, Wang X, et al. Molecular classification of human cancers using a 92-gene real-time quantitative polymerase chain reaction assay. Arch Pathol Lab Med 2006;130:465–473.

23. Rossi G, Papotti M, Barbareschi M, Graziano P, Pelosi G. Morphology and a limited number of immunohistochemical markers may efficiently subtype non-small-cell lung cancer. J Clin Oncol 2009;27:e141–e142.

24. Stang A, Pohlabeln H, Müller KM, Jahn I, Giersiepen K, Jöckel KH. Diagnostic agreement in the histopathological evaluation of lung cancer tissue in a population-based case-control study. Lung Cancer 2006;52:29–36.

25. CancerTYPE ID. 2011. bioTheranostics, Inc., San Diego, CA. Data on file.

26. Bishop JA, Benjamin H, Cholakh H, Chajut A, Clark DP, Westra WH. Accurate classification of non-small cell lung carcinoma using a novel microRNA-based approach. Clin Cancer Res 2010;16:610–619.

27. Lebanony D, Benjamin H, Gilad S, et al. Diagnostic assay based on hsa-miR-205 expression distinguishes squamous from non-squamous non-small-cell lung carcinoma. J Clin Oncol 2009;27:2030–2037.

28. Jemal A, Siegel R, Xu J, Ward E. Cancer statistics, 2010. CA Cancer J Clin 2010;60:277–300.

29. Minna JD. Neoplasms of the lung. In: Harrison's Principles of Internal Medicine, Kasper DL, Braunwald E, Hauser S, et al. New York: McGraw-Hill; 2005:506–515.

30. Marur S, Forastiere AA. Head and neck cancer: changing epidemiology, diagnosis, and treatment. Mayo Clin Proc 2008;83:489–501.

ABOUT THE AUTHORS

Affiliations: Dr. McGee is Laboratory Medical Director at Randolph Hospital, Asheboro, NC; Dr. Kesty is a Senior Medical Affairs Scientist, Dr. Erlander is the Chief Scientific Officer, and Dr. Schnabel is Director of Medical & Scientific Affairs at bioTheranostics, Inc., San Diego, CA.

Conflicts of interest: Dr. McGee has received consultancy fees and speakers' honoraria from bioTheranostics, Inc. Drs. Kesty, Erlander, and Schnabel are employees of bioTheranostics, Inc. and hold stock options in the company.

Posted with permission from the March 2011 issue of *Community Oncology* ® www.communityoncology.net. Copyright 2011. Elsevier. All rights reserved.
For more information on the use of this content, contact Wright's Media at 877-652-5295

76164